

CONTENTS



page 707

VIEWS

- 686** **Ah, That New Car Smell**
JADA Editor Marjorie K. Jeffcoat, D.M.D., underscores the role of change in the dental profession.

LETTERS

- 688** *JADA readers explore the brush biopsy technique, abfraction and the JADA Industry Advisory Board.*

NEWS

- 701** *A small piece of protein from the end of a human saliva molecule can kill several types of bacteria and fungi, researchers report at a meeting of the International Association for Dental Research. According to researchers from the State University of New York at Buffalo School of Dental Medicine, treating gingival infections with an antibiotic decreases two markers of inflammation throughout the body. JADA readers respond to the March Question of the Month.*

TRENDS



- 707** **The Impact of a State Children's Health Insurance Program on Access to Dental Care**
Mahyar Mofidi, D.M.D., M.P.H., and colleagues
The authors examine the impact of a new children's health insurance program in North Carolina on access to dental care.



- 715** **Dental Visits to Hospital Emergency Departments by Adults Receiving Medicaid: Assessing Their Use**
Leonard A. Cohen, D.D.S., M.P.H., M.S., and colleagues
Dr. Cohen and colleagues examine the use of hospital emergency departments for dental visits in Maryland after the state eliminated Medicaid reimbursement to dentists for adult emergency services.

RESEARCH

- 725** **Characteristics of Noncarious Cervical Lesions: A Clinical Investigation**
Tar C. Aw, D.D.S., M.S., and colleagues
In this in vivo investigation, the authors analyze the characteristics of noncarious cervical lesions in adults.

CLINICAL PRACTICE



- 734** **Dental Erosion Caused by Silent Gastroesophageal Reflux Disease**
Dena A. Ali, D.D.S.; Ronald S. Brown, D.D.S., M.S.; and colleagues
In this case report, the authors describe a patient with enamel erosion on his posterior and maxillary anterior teeth that resulted from gastroesophageal reflux disease.
- 738** **Bilateral Parotid Swelling Caused by Sarcoidosis**
Farisa Surattanont, D.D.S.; Louis Mandel, D.D.S.;
Barry Wolinsky, D.D.S., M.S.
The authors describe a patient with bilateral parotid swelling caused by sarcoidosis.

CLINICAL DIRECTIONS

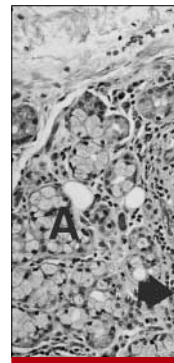
- 742 *A practicing dentist suggests steps that dentists can incorporate into their extraction protocol to prevent the occurrence of detrimental sequelae, such as edema and discomfort.*

COSMETIC & RESTORATIVE CARE

- 744 **The Effects of Two Cavity Preparation Methods on the Longevity of Glass Ionomer Cement Restorations: An Evaluation After 12 Months**

Kevin H-K. Yip, B.D.S., M.Ed., M.Med.Sc., Ph.D., and colleagues

In this study, the authors evaluate the effect of two cavity preparation methods on the initial survival of two more-viscous glass ionomer cements placed in the occlusal surfaces of permanent molars.



page 738

PRACTICE MANAGEMENT

- 752 **A New Perspective on Dental Malpractice: Practice Enhancement Through Risk Management**

Joseph P. Graskemper, D.D.S., J.D.

Dr. Graskemper advances the concept of risk management through greater involvement of the office staff in increasing patient communication.

GORDON J. CHRISTENSEN, D.D.S., M.S.D., Ph.D.

- 761 **The Curing Light Dilemma**

Dr. Christensen explores the advantages and disadvantages of various popular types of curing lights, and offers suggestions about the most logical ways to decide which curing light to use.

DENTISTRY & THE LAW

- 764 **Hawaii Court Dismisses Antitrust Suit Against Provider Groups**

Peter M. Sfikas, J.D.

Mr. Sfikas explores a ruling by a federal judge in Hawaii, who dismissed an antitrust lawsuit alleging that a number of parties, including a state medical association, had agreed to fix fees and other terms under which physicians would provide services for a health care provider network.

CONTINUING EDUCATION

- 767 *JADA's continuing education program highlights the impact of a state children's health insurance program on access to dental care, dental visits to hospital emergency departments by adults receiving Medicaid, dental erosion caused by silent gastroesophageal reflux disease, and the effects of two cavity preparation methods on the longevity of glass ionomer cement restorations.*

705 **CYBERNEWS**

789 **ADVERTISING STANDARDS**

791 **FOR THE DENTAL PATIENT**

720 **QUESTION OF THE MONTH**

773 **CLASSIFIED ADVERTISING**

792 **INDEX TO ADVERTISERS**

758 **DENTAL PRODUCT SPOTLIGHT**