



**Oral cancer and its detection: History-taking  
and the diagnostic phase of management**

JAMES J. SCIUBBA

*J Am Dent Assoc* 2001;132;12S-18S

---

*The following resources related to this article are available online at  
[jada.ada.org](http://jada.ada.org) ( this information is current as of July 5, 2009 ):*

**Updated information and services** including high-resolution figures, can be found in the online version of this article at:

[http://jada.ada.org/cgi/content/full/132/suppl\\_1/12S](http://jada.ada.org/cgi/content/full/132/suppl_1/12S)

Information about obtaining **reprints** of this article or about permission to reproduce this article in whole or in part can be found at:

<http://www.ada.org/prof/resources/pubs/jada/permissions.asp>

# Oral cancer and its detection

## History-taking and the diagnostic phase of management

JAMES J. SCIUBBA, D.M.D., Ph.D.

**O**ral squamous cell carcinoma, the most common oral malignancy, often presents a clinical diagnostic challenge to the dental practitioner, particularly in its early stages of development. While the majority of such cancers are associated with a long history of smoking and

**The diagnosis of oral precancer and cancer remains a challenge to the dental profession, particularly in the detection, evaluation and management of early-phase alterations or frank disease.**

alcohol abuse, there is an increasing awareness of oral cancers developing in those who do not engage in either of these risk behaviors. Therefore, the dentist must consider all patients at risk and act accordingly in the history-taking and examination phases of the dental visit. By recognizing, and establishing a diagnosis of, oral cancer development in its early phase, the clinician can help the patient greatly increase his or her chances for a cure and a normal, full life. On the other hand, a much poorer outcome results when presentation and diagnosis are established at a later, more advanced stage. As clinicians, we can greatly influence disease outcome and quality of life when we confront oral mucosal alterations representing early

squamous cell carcinoma in our patients.

### THE IMPORTANCE OF THE INITIAL INTERVIEW

The diagnostic phase of patient management begins with an assessment of the medical history and its potential impact on the dental history and overall management of any oral disease or condition. Health history questionnaires must include pertinent questions relative not only to general health, but also to

**Background.** Comprehensive patient evaluation begins with an accurate analysis of all factors of the patient's history before the physical examination is performed. Risk factor identification is particularly important in most cases of oral mucosal dysplasia and carcinoma, as it alerts the clinician to an increased susceptibility for such alterations. The armamentarium of the dentist, which ranges from noninvasive indicators to a scalpel biopsy, permits a thorough evaluation of any observed mucosal changes. Newer additions to this armamentarium have been developed and are emerging that aid in the process of characterizing lesions, thereby facilitating appropriate management.

**Methods.** The author presents methods of assessing and analyzing a patient's oral health status. He discusses carcinogens and cofactors, as well as dietary considerations, in the development of oral mucosal precancer and cancer. He also presents details of the clinical evaluation, which can lead the clinician to possible further evaluation and analysis by an expanding array of diagnostic tools.

**Results.** The article identifies the factors a clinician should consider when evaluating the dental patient, from initial presentation and risk factor identification to the use of traditional assessment parameters. New and evolving diagnostic tools, coupled with cell and tissue characterization by an oral and maxillofacial pathologist, remain critical in terms of patient management and in maintaining optimum standards of care.

**Conclusions and Clinical Implications.** A comprehensive oral examination must include integration of each patient's in-depth health history and the physical findings. Appreciation of subtle surface changes as a possible harbinger of pathology and the traditional process of observation combined with new and emerging tools now allow for earlier diagnosis that will translate into improved outcomes.



what the practitioner must know as the oral and head and neck examination and treatment plan evolve.

In conducting the initial patient interview, the dentist should assess health-related risk factors such as prior and current illness, indications for treatment, health habits and behaviors, and lifestyle. Evaluation of surgical experience, hospitalizations, current medications, dietary patterns, and smoking and alcohol consumption are key to understanding the general health of a patient. Obtaining this information is pivotal to determining the potential for oral diseases and whether dental treatment will require modification.

## RISK FACTORS TO NOTE

**Tobacco use.** The morbidities of smoking and use of other tobacco products are well-known.<sup>1,2</sup> Because of this important potential impact, the role of dentistry in tobacco control is addressed elsewhere in this supplement.<sup>3</sup> Consumption of other forms of tobacco, such as smokeless tobacco, snuff and paan<sup>4,5</sup> (areca nut, tobacco, betel leaf, snuff, chewing tobacco, slaked lime, spices), are prevalent throughout the developing countries of the world and in areas of the United States. Many of these customs are being practiced in the United States, especially given the influx of people from cultures in which the practices of non-Western tobacco use are the norm.<sup>6</sup> The dominant risk factor in the United States, however, is cigarette smoking with its direct health-related morbidities, including the development of cancer of the upper aerodigestive tract. Also, a strong relationship has been noted between development of oral premalignancy in the form of erythroplakia and use of chewing tobacco combined with alcohol consumption.<sup>7</sup>

**Alcohol consumption.** Oral cancer development and the consumption of alcohol are strongly linked, particularly when there is concurrent tobacco use. Synergistic effects of alcohol and tobacco have been demonstrated, so if concurrent alcohol and tobacco use is noted during the history-gathering phase of treatment, the dental practitioner should be alert to the patient's increased potential for oral cancer.<sup>8</sup>

.....  
**If concurrent alcohol and tobacco use is noted during the history-gathering phase of treatment, the dental practitioner should be alert to the patient's increased potential for oral cancer.**  
 .....

Alteration of the oral mucosa's permeability induced by ethanol in vitro has been shown to increase the degree of tobacco-associated carcinogen penetration into mucosa.<sup>9</sup> This alteration is one mechanism suggested as a possible explanation for this increased risk. In addition, acetaldehyde, a direct metabolite of alcohol, is a carcinogen and may be produced both systemically and by the oral microflora.<sup>10-12</sup>

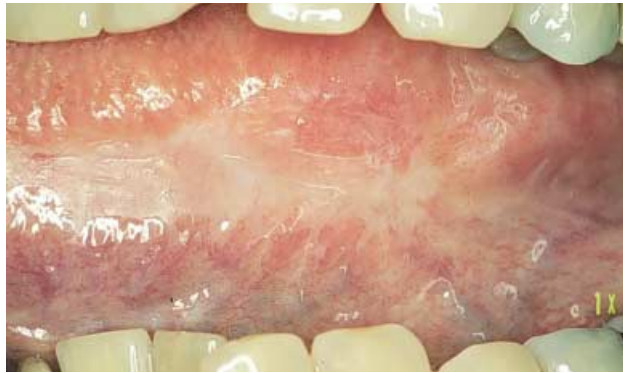**Diet.** Recently, attention has been directed toward diet and its influence on the development of precancer and cancer. More specifically, the possible role of micronutrient ingestion with an associated antioxidant effect has been emphasized. Natural carotenoid compounds; dietary selenium; folate; and vitamins A, C and E have been stated to offer protective effects regarding cancer development.<sup>13-16</sup> Further insights into development of oral cancer may be gained by understanding the possible impact of a diminution of serum levels of certain vitamins and nutrients in those who smoke.<sup>17</sup>

**Lifestyle.** The lifestyle behaviors of a patient will play a role in determining his or her overall risk of developing oral and pharyngeal cancer.<sup>18</sup> Accordingly, clinicians should consider referring to dietary and substance abuse treatment professionals any patient who engages in high-risk behaviors in terms of both alcohol use and dietary practices. In addition, the emerging contribution of ethnic and genetic susceptibility also must be considered as a potentially important modifying factor.<sup>19,20</sup> When such risk factors can be discovered readily, they also can help guide patient care.

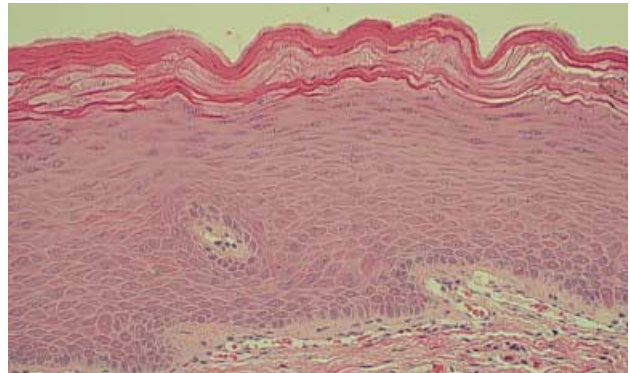
## HEALTH HISTORY FACTORS

**Sun exposure and protection.** The health history interview should include questions about sun exposure and the use of lip sunscreen and protective coverings. The dentist should emphasize the strong risk of developing lower lip squamous cell carcinoma as a result of sunlight, or actinic, exposure over a period of many years.<sup>21</sup>

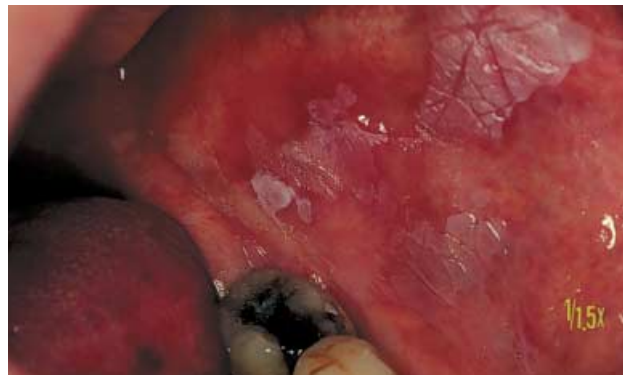**Surgeries and medications.** The dentist should determine whether the patient has any history of surgery, as well as any medications he



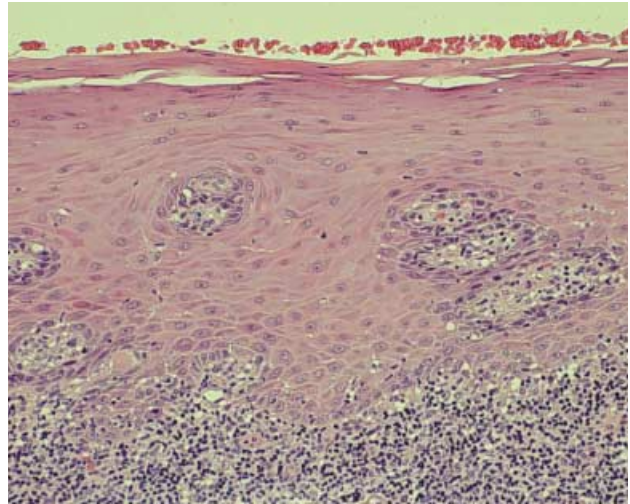
**Figure 1. A. Diffuse, homogeneous leukoplakia of the lateral and ventral surfaces of the tongue.**



**B. Surface parakeratosis overlies a benign stratified squamous epithelium. The underlying lamina propria shows no evidence of an inflammatory infiltrate, and all findings suggest an entirely benign process.**



**Figure 2. A. Patchy leukoplakia with a fissured surface was noted in association with surrounding erythema. No induration was present.**

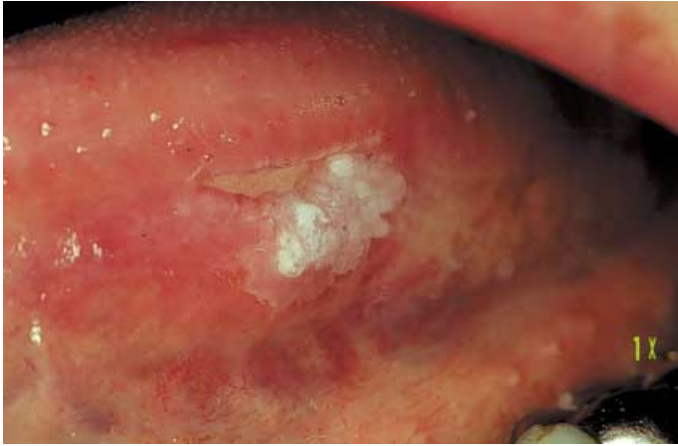

**B. An intense diffuse lichenoid inflammatory infiltrate is located within and extends beyond the lamina propria. A thin orthokeratotic layer covers the overlying epithelium, while the epithelial cell morphology is benign.**

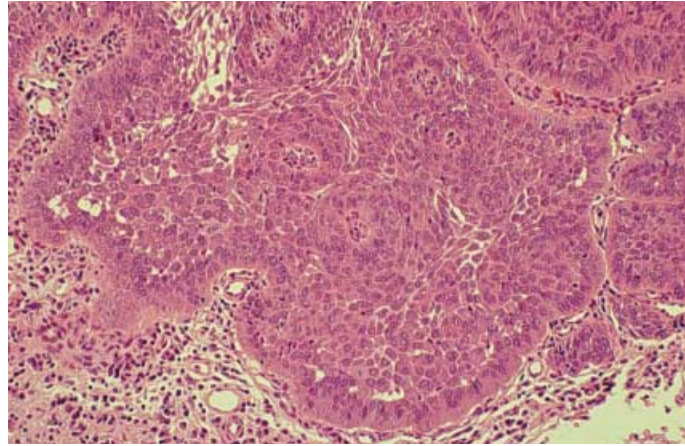
or she is taking. The dental team must be aware of the considerably increased risk of cancer development in patients who have undergone organ transplantation and the subsequent long-term immunosuppressive therapy. The overall relative increase in risk of cancer development as a corollary to complications of liver transplantation and extended immunosuppression has been demonstrated at a risk level of 4.3 compared with that of the general population.<sup>22</sup> Similarly, the risk of solid cancer development in patients who have undergone bone marrow transplantation is twice that of a comparable normal population.<sup>23</sup> These assessments are especially important considering that such procedures are becoming more widespread among Americans.

**Sexual practices and human papilloma virus.** Finally, a recent study by Gillison and colleagues<sup>24</sup> identified high-risk human papilloma virus 16 in specimens of lingual and palatine tonsil squamous cell carcinomas. Specific human papilloma virus localization in tumor cells at

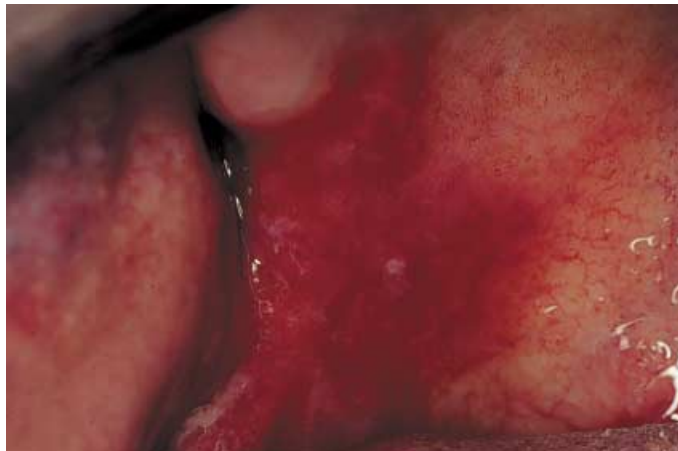preinvasive, invasive and metastatic lymph node sites and its probable integration into the genomic structure of some tumors have been shown.<sup>24</sup> Also of note is the improved survival and clinical course of this form of oropharyngeal carcinoma compared with that of human papilloma virus-negative oropharyngeal cancers.<sup>24</sup> Therefore, the implication of transmissibility of this virus becomes an issue, when certain sexual behaviors involving orogenital contact may possibly affect the overall risk of developing a subset of oral/oropharyngeal squamous cell carcinomas. Thus, the clinician may wish to ask the patient about whether he or she engages in these practices. Yet to be studied are the possible synergistic effects of alcohol and tobacco and exposure to that form of human papilloma virus.



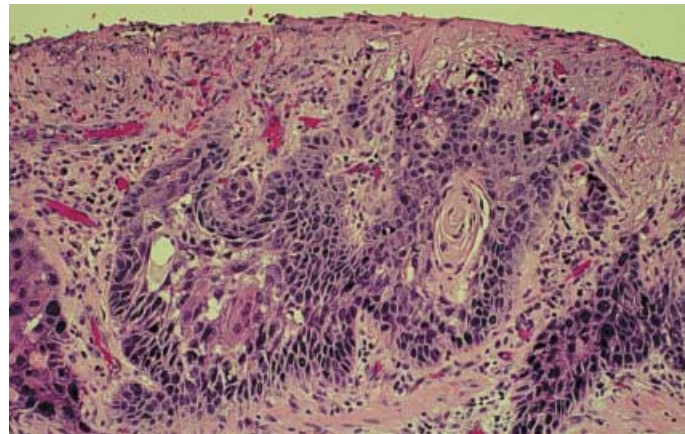
**Figure 3. A. A superficially ulcerated keratotic region on the ventral surface of the tongue, with granular surface texture focally.**



**B. Severe epithelial dysplasia is characterized by abnormal cell morphology through the entire epithelial layer. These abnormalities consist of disordered cell arrangement; enlarged, hyperchromatic nuclei; reduced cell cohesion; and lack of cellular maturation.**



**Figure 4. A. The soft palate, retromolar trigone and posterior maxillary tuberosity are involved with erythroplakia. Note the sharp margins with mere traces of keratinization present as tiny papules.**

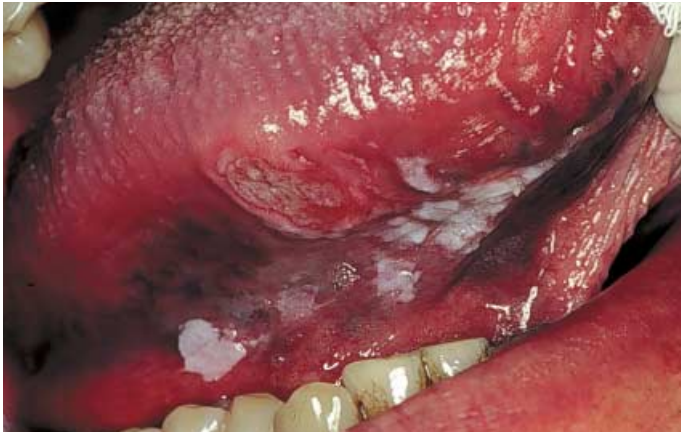

**B. Infiltrating squamous cell carcinoma demonstrating deeply hyperchromatic nuclei, focal dyskeratosis and an ulcerated surface.**

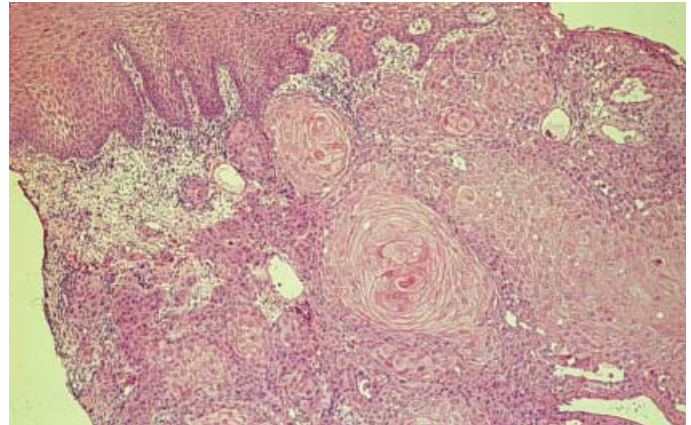
### **CLINICAL EVALUATION: EXAMINATION AND FINDINGS**

Oral precancer and cancer demonstrate a wide range of clinically detectable alterations (Figures 1-5) that may range from an early subtle change in surface texture, color or elasticity to a more obvious lesion. Surface changes often have mixed red and white features with few, if any, associated symptoms. Concomitant change in mucosal texture by way of firmness or induration on digital palpation, friability on slight manipulation and distortion of normal anatomy can be seen, while more advanced disease may feature lesions fixed to surrounding and deeper tissues, often without attendant pain or symptoms.

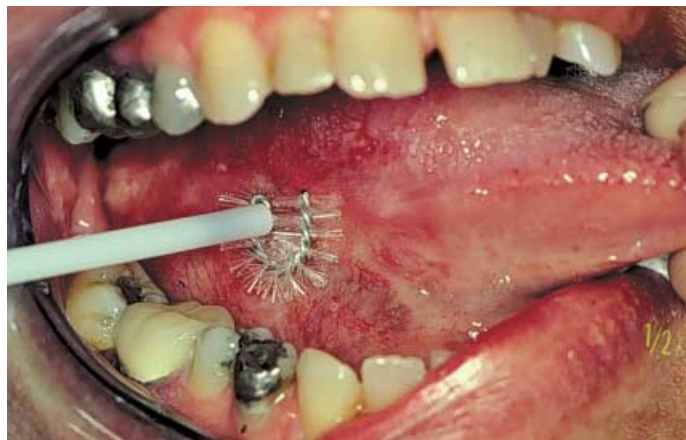As clinicians, we are responsible for recognizing and detecting early or incipient changes of the oral mucosa; this is well within the community standard of care. Most early-stage oral carcinomas appear to be seemingly innocent alterations, in the form of focal color change (red, white or mixed), surface textural change (erosion, keratosis, granularity or fissuring) or both. These changes represent cellular alterations that result from genomic changes within the surface epithelial cell population. Such changes include alterations in DNA content,<sup>25</sup> loss of heterozygosity and genetic alterations in a stepwise progressive fashion that lead to formation of invasive squamous cell carcinoma.<sup>26</sup> With clinical progression of early squamous cancer to intermediate and later-stage disease,



**Figure 5. A.** At the initial visit of a heavy smoker, an ulcerated, indurated, nontender area was located along the lateral/ventral surfaces of the tongue adjacent to a speckled form of leukoplakia. An incisional biopsy performed at the first visit confirmed the clinical suspicion of invasive squamous cell carcinoma.



**B.** Deeply invasive, well-differentiated squamous cell carcinoma, composed of epithelial sheets containing focal areas of keratin pearl formation beneath the proliferating tumor.



**Figure 6.** The circular, stiff-bristled brush biopsy instrument is applied to the surface of a mucosal surface alteration along the ventral tongue surface with a twisting motion until pinpoint bleeding is seen. The collected cells then are transferred to a glass slide.

additional clinical signs become evident—including ulceration, induration/fixation, bone invasion, tooth mobility and pain. Locoregional extension to draining lymph nodes generally occurs in the later stages of disease progression as a result of lymphatic vessel permeation by invasive tumor, thus increasing the staging to levels less likely to be successfully managed.

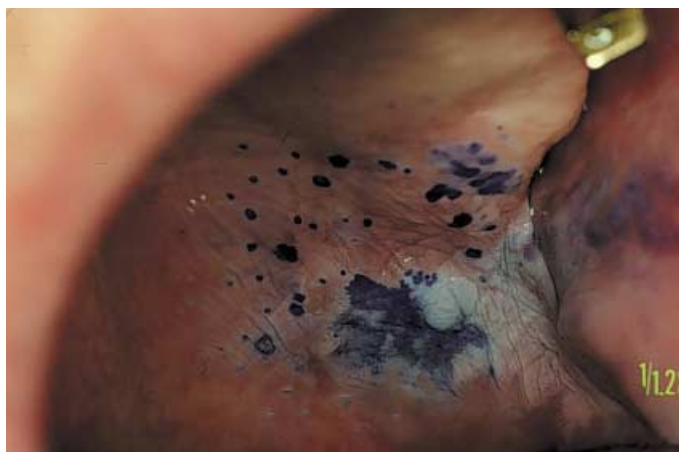Intraoral precursor lesions, generally in the form of leukoplakia (usually of a speckled red and white or heterogeneous type) are at-risk sites because of the high proportion of biopsy specimens demonstrating the presence of dysplasia or frankly malignant (invasive) disease at

initial presentation. This observation has been established in the classic study of Waldron and Shafer,<sup>27</sup> who noted 43 percent of floor-of-the-mouth leukoplakias to be dysplastic or malignant at the initial biopsy. In a separate and likewise seminal publication by Kramer and colleagues,<sup>28</sup> a 27 percent rate of cancer was noted in ventral tongue/floor-of-the-mouth sites at the initial visit, with an additional 24 percent of cases noted on follow-up.

#### **EARLY DETECTION AND DIAGNOSIS OF ORAL CANCER**

**Observation and biopsy.** Despite improved surgical approaches, vastly improved reconstruction techniques, and advances in radiation and medical oncology, the single most effective route to improving the long-term outcome of oral squamous cell carcinoma is early diagnosis, coupled with appropriate treatment. Dentists must be keenly aware of oral mucosal alterations, which may herald early or preinvasive cancer. Ideally, any observed suspicious mucosal abnormality must be sampled using a scalpel or punch tissue biopsy and be submitted to an oral and maxillofacial pathologist for evaluation. Obtaining architectural and cytologic rendering in this way is the “gold standard” for establishing the nature of a mucosal abnormality. Practitioners may opt to refer their patients for scalpel or punch tissue biopsies.

Alternatively, as a way to obtain useful and accurate information concerning a possible precancer or carcinoma, a new and emerging technology—a brush biopsy—may be used (Figure



**Figure 7. A wide alteration of the soft palate as typical leukoplakia was stained with toluidine blue O dye. After acetic acid rinsing, regions of increased dye retention were present, alerting the clinician to the need for further analysis of cell and tissue pathology.**

6).<sup>29</sup> In this procedure, the dental practitioner samples an alteration of the surface mucosa by collecting of full thickness of mucosal epithelial cells, placing them on a slide and performing a fixation step before forwarding the slide to the laboratory. This process may be especially useful when the practitioner is uncertain whether the lesion warrants a scalpel or a punch biopsy.

When several surface abnormalities are present, a clinician may consider the use of vital staining with toluidine blue O to aid in clinical judgment as to the identification of areas that are more likely to represent dysplasia or cancer and require biopsy (Figure 7).<sup>30</sup> The specific indications for a scalpel or punch biopsy rather than a brush biopsy would include an obvious cancer, a highly suspicious lesion or a lesion in a person at high risk for whom a definitive diagnosis would be necessary as soon as possible. The brush biopsy, on the other hand, is better used for evaluation of lesions of unknown significance or behavior. Alternatively, surface mucosal lesions, which have been duly noted and have remained under observation only, may be sampled by the brush biopsy and analyzed on a periodic basis. Either method will provide important information to the clinician and the patient concerning further options.

**The specific indications for a scalpel or punch biopsy rather than a brush biopsy would include an obvious cancer, a highly suspicious lesion or a lesion in a person at high risk for whom a definitive diagnosis would be necessary as soon as possible.**

**Chemoluminescent light.** A new technology currently used as a cost-effective screening device in gynecologic settings directs chemoluminescent light over mucosa previously rinsed with dilute acetic acid.<sup>31,32</sup> Affected or abnormal mucosa appears as an opaque “acetowhite” alteration that can be studied further by more traditional biopsy techniques. The U.S. Food and Drug Administration recently cleared a 510(k) application for the chemoluminescent light’s use in evaluating oral mucosa, which means that the new intended use of the device has been demonstrated to be substantially equivalent to already approved fields of technology and is ready for marketing without further approval for use. Thus, this approach, which is useful in the field of gynecology for cervical cancer screening, has been extended for oral cancer examinations. Accordingly, this adjunctive procedure also may be useful in identifying sites in the oral cavity requiring biopsy.

## CONCLUSIONS

The diagnosis of oral precancer and cancer remains a challenge to the dental profession, particularly in the detection, evaluation and management of early-phase alterations or frank disease. Our appreciation of key components of a patient’s health history and habits, coupled with a heightened awareness of subtle or early alterations, remain crucial in responding to this challenge. Correlating a patient’s health history, clinical changes noted, and the relative risk associated with both of these with prompt use of appropriate and proven diagnostic modalities will ensure that clinicians provide patients with the optimal level of management. This, in turn, will produce the best possible long-term outcome. ■

Dr. Sciubba is the director, Dental and Oral Medicine, Department of Otolaryngology, Head and Neck Surgery, Johns Hopkins Medical Center, 601 N. Caroline St., Room 6243, Baltimore, Md. 21287-0910, e-mail “jsciubb@jhmi.edu”. Address reprint requests to Dr. Sciubba.

1. La Vecchia C, Tavani A, Franceschi S, Levi F, Corrao G, Negri I. Epidemiology and prevention of oral cancer. *Oral Oncol* 1997;33:302-12.
2. Blot WJ, McLaughlin JK, Winn DM, et al. Smoking and drinking in relation to oral and pharyngeal cancer. *Cancer Res* 1988;48:3282-7.
3. Tomar SL. Dentistry’s role in tobacco control. *JADA* 2001;132(supplement):30S-35S.

4. Vora AR, Yeoman CM, Hayter JP. Alcohol, tobacco and paan use and understanding of oral cancer risk among Asian males in Leicester. *Br Dent J* 2000;188(8):444-51.
5. Merchant A, Husain SS, Hosain M, et al. Paan without tobacco: an independent risk factor for oral cancer. *Int J Cancer* 2000;86(1):128-31.
6. Zain RB. Cultural and dietary risk factors of oral cancer and pre-cancer: a brief overview. *Oral Oncol* 2001;37(3):205-10.
7. Hashibe M, Mathew B, Kuruvilla B, et al. Chewing tobacco, alcohol, and the risk of erythroplakia. *Cancer Epidemiol Biomarkers Prev* 2000;9(7):639-45.
8. Macfarlane GJ, Macfarlane TV, Lowenfels AB. The influence of alcohol consumption on worldwide trends in mortality from upper aerodigestive tract cancers in men. *J Epidemiol Community Health* 1996;50:636-9.
9. Du X, Squier CA, Kremer MJ, Wertz PW. Penetration of N-nitrosornicotine (NNN) across oral mucosa in the presence of ethanol and nicotine. *J Oral Pathol Med* 2000;29(2):80-5.
10. Fang JL, Vaca CE. Detection of DNA adducts of acetaldehyde in peripheral white blood cells of alcohol abusers. *Carcinogenesis* 1997;18:627-32.
11. Takeshita T, Kawai T, Morimoto K. Elevated levels of hemoglobin-associated acetaldehyde related to alcohol drinking in the atypical genotype of low Km aldehyde dehydrogenase. *Cancer Res* 1997;57:1241-3.
12. Homann N, Jousimies-Somer H, Jokelainen K, Heine R, Salaspuro M. High acetaldehyde levels in saliva after ethanol consumption: methodological aspects and pathogenetic implications. *Carcinogenesis* 1997;18:1739-43.
13. Hennekens CH, Stampfer MJ, Willett W. Micronutrients and cancer chemoprevention. *Cancer Detect Prev* 1984;7:147-58.
14. Ramaswamy G, Rao VR, Kumaraswamy SV, Anantha N. Serum vitamins' status in oral leukoplakias: a preliminary study. *Eur J Cancer Oral Oncol* 1996;32B:120-2.
15. Enwonwu CO, Meeks VI. Bionutrition and oral cancers in humans. *Crit Rev Oral Biol Med* 1995;6(1):5-17.
16. Garewal H. Antioxidants in oral cancer prevention. *Am J Clin Nutr* 1995;62:1410S-6S.
17. Cowan CG, Calwell EI, Young IS, McKilbp DJ, Lamey DJ. Antioxidant status of oral mucosal tissue and plasma levels in smokers and non-smokers. *J Oral Pathol Med* 1999;28:360-3.
18. Morse DE, Pendrys DG, Katz RV, et al. Food group intake and the risk of oral epithelial dysplasia in a United States population. *Cancer Causes Control* 2000;11(8):713-20.
19. Kahn FA, Robinson PG, Warnakulasuriya KA, Newton JT, Gelbier S. Predictors of tobacco and alcohol consumption and their relevance to oral cancer control amongst people from minority ethnic communities in the South Thames health region, England. *J Oral Pathol Med* 2000;29:214-9.
20. Bouchardy C, Hirvonen A, Coutelle C, Ward PJ, Dayer P, Benhamou S. Role of alcohol dehydrogenase 3 and cytochrome P-450E1 genotypes in susceptibility to cancers of the upper aerodigestive tract. *Int J Cancer* 2000;87:734-40.
21. Campisi C, Margiotta V. Oral mucosal lesions and risk habits among men in an Italian study population. *J Oral Pathol Med* 2001;30(1):22-8.
22. Haagsma EB, Hagens VE, Schaapveld M, et al. Increased cancer risk after liver transplantation: a population-based study. *J Hepatol* 2001;34(1):84-91.
23. Bhatia S, Louie AD, Bhatia R, et al. Solid cancers after bone marrow transplantation. *J Clin Oncol* 2001;19(2):464-71.
24. Gillison ML, Koch WM, Capone RB, et al. Evidence for a causal association between human papillomavirus and a subset of head and neck cancers. *J Natl Cancer Inst* 2000;92(9):709-20.
25. Sudbo J, Kildal W, Risberg B, Koppang HS, Danielsen HE, Reith A. DNA content as a prognostic marker in patients with oral leukoplakia. *N Engl J Med* 2001;344:1270-8.
26. Califano J, van der Reit P, Westra W, et al. Genetic progression model for head and neck cancer: implications for field cancerization. *Cancer Res* 1996;56:2988-92.
27. Waldron CA, Shafer WG. Leukoplakia revisited: a clinicopathologic study 3256 oral leukoplakias. *Cancer* 1975;36:1386-92.
28. Kramer IR, El-Labban N, Lee KW. The clinical features and risks of malignant transformation in sublingual keratosis. *Br Dent J* 1978;144:171-80.
29. Sciubba JJ. Improving detection of precancerous and cancerous oral lesions: computer-assisted analysis of the oral brush biopsy—U.S. Collaborative Oral CDx Study Group. *JADA* 1999;130:1445-57.
30. Silverman S Jr, Migliorati C, Barbosa J. Toluidine blue staining in the detection of oral precancerous and malignant lesions. *Oral Surg Oral Med Oral Pathol* 1984;57:379-82.
31. Lonky NM, Edwards G. Comparison of chemoluminescent light versus incandescent light in the visualization of acetowhite epithelium. *Am J Gynecol Health* 1992;6(1):11-5.
32. Louidice L, Abbiati R, Boselli F, et al. Improvement of Pap smear sensitivity using a visual adjunctive procedure: a co-operative Italian study on speculscopy (GISPE). *Eur J Cancer Prev* 1998;7:295-304.