

**Diagnosing bulimia nervosa with parotid gland swelling**

LOUIS MANDEL and SIAMAK ABAI  
*J Am Dent Assoc* 2004;135;613-616

---

*The following resources related to this article are available online at [jada.ada.org](http://jada.ada.org) ( this information is current as of March 20, 2010 ):*

**Updated information and services** including high-resolution figures, can be found in the online version of this article at:

<http://jada.ada.org/cgi/content/full/135/5/613>

This article appears in the following **subject collections**:

Periodontics <http://jada.ada.org/cgi/collection/periodontics>

Information about obtaining **reprints** of this article or about permission to reproduce this article in whole or in part can be found at:

<http://www.ada.org/prof/resources/pubs/jada/permissions.asp>

## CASE REPORT

# Diagnosing bulimia nervosa with parotid gland swelling

LOUIS MANDEL, D.D.S.; SIAMAK ABAI

Eating disorders have become a relatively common problem in our society, particularly among young women seeking to have the ideal figure. These disorders include anorexia nervosa, or AN; bulimia nervosa, or BN; and patients with a high incidence of crossover between AN and BN. People with AN deliberately starve themselves, while people with BN will induce vomiting after an episode of binge eating, often followed by periods of fasting.

**The etiology of parotid gland swelling in patients with bulimia nervosa can elude dentists, because patients usually are secretive about their purging episodes.**

BN characteristically starts in a young woman whose self-image is that she is obese. Feelings of low self-esteem and guilt develop, and the young woman resorts to dieting, which may not be entirely successful. She may lose some weight, but simultaneous hunger ensues. An eating binge results, which the young woman counters with self-induced purging. She soon realizes that episodes of overeating can be countered by vomiting. Now there is less tendency to limit the number of binge/vomiting cycles. Before long the young woman resorts to bingeing, vomiting or both not only when she hungry but also when she is depressed, tense or anxious.<sup>1</sup> The self-induced vomiting usually is carried out

in secret. Emetics, diuretics and laxatives frequently are used as adjunctive agents.

People with BN may vomit as few as two times a day or as many as 20 times a day.<sup>1,2</sup> The average caloric intake during an eating binge is 3,500 calories, but many people with BN will ingest as many as 50,000

**Background.** The authors describe bulimia nervosa, or BN, and its effect on the parotid gland. The associated asymptomatic bilaterally enlarged parotid glands often present a diagnostic dilemma.

**Case Description.** The authors present a case of a 22-year-old woman with BN who had bilateral parotid gland swelling, serum electrolyte alteration and no dental stigmata. Her principal concern was the associated cosmetic deformity.

**Clinical Implications.** Because patients with BN who have parotid gland swelling usually are secretive about their purging, the diagnosis may be confirmed by conducting a clinical examination and a serum electrolyte study. Prompt diagnosis can avoid serious medical complications.



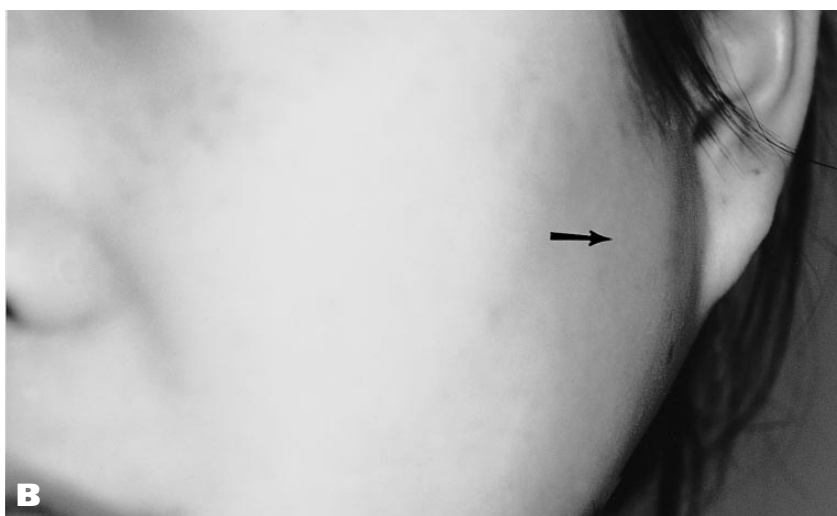
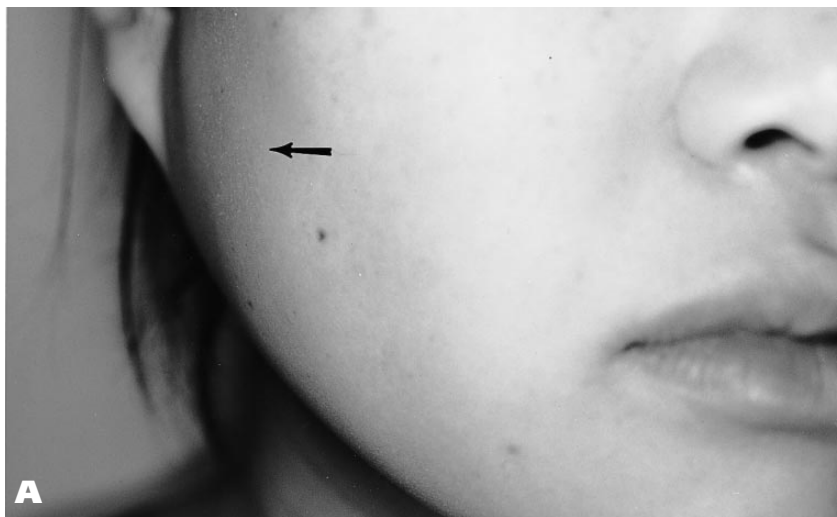calories in a 24-hour period.<sup>3-5</sup>

Classically, but not always, the person is a female college student who has resorted to the practice for 5.8 years.<sup>6</sup> It is estimated that up to 19 percent of college women have severe cases of BN.<sup>4,7,8</sup> Some reports indicate that 1 to 10 percent of Western women practice this behavior at some time in their lives.<sup>9-11</sup> Only 5 to 10 percent of people with BN are male.<sup>7,9</sup>

Because of the surreptitious nature of BN and because of the possible development of serious complications, dentists' familiarity with the symptoms of BN is mandatory. In this article, we review the pathophysiology of BN, its salivary gland symptomatology and the role of serum electrolytes, as well as present a case report.

## CASE REPORT

A 22-year-old female college student, who was in otherwise excellent health, was referred to Columbia University's Salivary Gland Center, or SGC, New York City, in February 2003 by her psychiatrist because she had a one-year



**Figure 1. A. Right parotid gland swelling (arrow). B. Left parotid gland swelling (arrow).**

history of bilateral parotid gland swelling (Figure 1). The patient was concerned about the cosmetic effect caused by the swellings.

From the time of onset, the parotid gland swelling was persistent, painless and did not fluctuate in size. Palpation confirmed that the enlarged parotid glands were painless and normal in tone. We did not see any cervical lymphadenopathy. Intraorally, the mucosa was normally moist. All salivary ducts were patent with a clear and adequate salivary flow exiting from each parotid orifice when the gland was manually milked. The patient was caries-free, and no restorations were present. There were no signs of enamel erosion or periodontal abnormalities. The patient was excellent at following an oral hygiene regimen.

On completion of the intraoral examination, the patient volunteered further information about her medical background. She admitted to having a six-year history of BN. She stated that when she was in her teens, she became concerned about her weight and turned to self-induced vomiting after overeating as a weight-control measure. Over time, the number of emetic episodes increased, and she used them as a means of decreasing stress. Her acceptance into a prestigious university two years before and mental pressures concerning her academic performance led to a significant increase in the number of emetic episodes. She admitted that until recently she had vomited approximately 20 times each day.

Because she became increasingly alarmed about the parotid gland swellings, she sought medical care in June 2002, without admitting to the emetic problem. A computerized tomography, or CT, scan was performed, and she was told that the parotid glands were enlarged and denser for unknown reasons but that no pathology was present (Figure 2). She was not offered any medical treatment.

In December 2002, she visited another physician, who performed a serology evaluation. The patient's serum potassium level was abnormally low (3.2 millimolar per liter; normal = 3.5-5.5 mmol/L). Hypokalemia was the only abnormality uncovered by the physician. At this point, the patient told her physician that she had BN. After potassium replacement therapy, she was referred to a psychiatrist and prescribed the antidepressant paroxetine hydrochloride.

When the patient came to the SGC, she had been taking paroxetine hydrochloride for the previous two months, and she had weekly appointments with her psychiatrist. She said that she was vomiting only twice each day. However, because of her concern about the parotid gland swelling, her psychiatrist referred her to the SGC.

We made a diagnosis of emetically induced

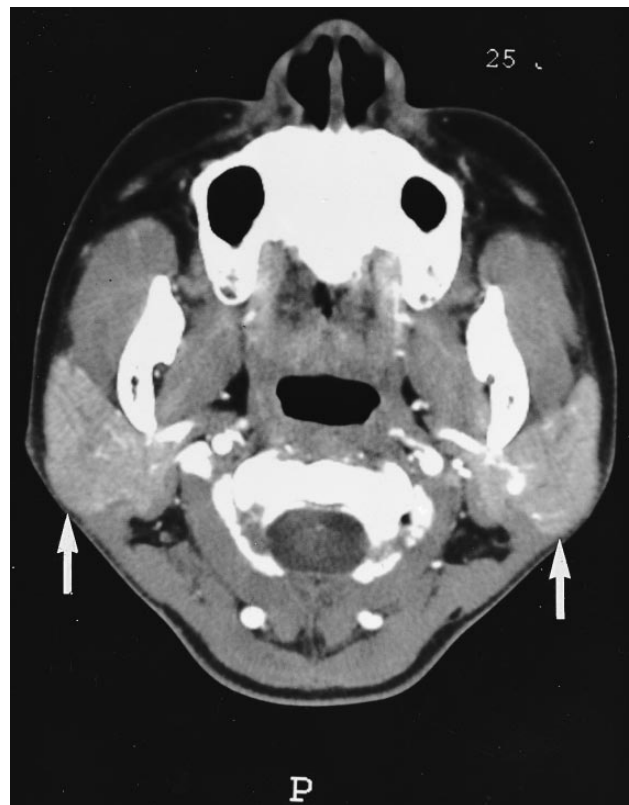bilateral parotid gland swelling after integrating her history and clinical findings with the blood chemistry.

## DISCUSSION

Bilateral—and occasionally unilateral—parotid gland swelling is not unusual in people with BN; the incidence of parotid gland swelling has been reported to occur in 10 to 15 percent of people with BN.<sup>12,13</sup> The submandibular salivary gland is involved infrequently. The exact pathogenesis has not been determined. However, it generally is accepted that multiple emetic episodes cause an autonomic neuropathy.<sup>10,14-18</sup> With sympathetic nerve impairment, individual acinar cells enlarge because of zymogen granule engorgement.<sup>14,15,17,19,20</sup> One explanation is that the sympathetic nerve supply to the secreting acinar cell is concerned with the production and secretion of zymogen, the precursor of amylase. Because of sympathetic nerve dysfunction, there may be an increase in zymogen storage in the cell, owing to increased production, decreased secretion of the granules or both. The ensuing cellular enlargement, which is evidenced by fine-needle aspiration biopsy and electron microscopy, leads to the clinically visible gland enlargement.<sup>18</sup> A CT scan of the parotid gland can testify further to the cause. Not only will parotid hypertrophy be seen, but increases in gland density and contrast enhancement also will be observed (Figure 2). The normally present lucent intraparotid fat is replaced by the acinar hypertrophy, which results in the increased parotid gland density. Contrast enhancement reflects the augmented vascularity associated with gland hypertrophy.

Work hypertrophy also has been suggested as an alternative hypothesis for the parotidomegaly.<sup>2,13,19</sup> Chronic autonomic stimulation from frequent and repeated emetic episodes is assumed to be the cause of the cellular enlargement.

At the SGC, we are aware that a serum electrolyte study is an important tool that can be used to diagnose multiple vomiting episodes as the cause of parotid gland swelling.<sup>21</sup> People with BN lose large quantities of fluid<sup>1</sup> owing to purging and the often-adjunctive use of diuretics and laxatives. To preserve extracellular fluid volume, hyperaldosteronism develops and increases sodium resorption with accompanying bicarbonate from the kidney tubules. Serum potassium is lost when it is secreted into the kidney tubules in exchange for the aldosterone-enhanced sodium



**Figure 2. Computerized tomography scan with contrast of moderately enlarged parotid glands (arrows).**

resorption. The potassium loss is amplified by laxative-induced diarrhea and diuretic-induced urination.<sup>22-26</sup> Further serum potassium loss occurs when potassium moves into cells in exchange for intracellular hydrogen, which is exiting in response to a developing extracellular fluid alkalosis.

A depletion of serum chloride also may occur. The multiple emetic episodes that result in gastric hydrochloric acid loss can lead to a hypochloremia. As with potassium, serum chloride's loss may be accentuated with the use of laxatives and diuretics. Although our patient had hypokalemia, the serum chloride was within normal limits, and a metabolic alkalosis was not present. Alterations in all serum electrolytes are not always found. Obviously, the finding of abnormal serum electrolytes is dependent on many factors, including duration and frequency of the vomiting, the use of adjunctive agents and nutritional replacement.

The significance of conducting an electrolyte study is that most patients with BN are secretive about it, whereas our patient was not. Positive results from a serum electrolyte study can offer



Dr. Mandel is the director, Salivary Gland Center, Assistant Dean and Clinical Professor (Oral and Maxillofacial Surgery), Columbia University School of Dental and Oral Surgery, New York–Presbyterian Hospital (Columbia Campus), 630 West 168th St., New York, N.Y. 10032, e-mail "lm7@columbia.edu". Address reprint requests to Dr. Mandel.



Mr. Abai is a research assistant, Salivary Gland Center, and a fourth-year dental student, Columbia University School of Dental and Oral Surgery, New York.

dentists a means of substantiating a presumptive diagnosis of a vomiting-induced parotid hypertrophy. Alterations in electrolyte levels can be life-threatening

and often require hospitalization. Cardiac dysrhythmias, muscle cramps, hypotension and menstrual irregularity are some of the predictable results of alterations in electrolyte levels.

In addition to restoring electrolyte levels and advising hospitalization when indicated, treatment for people with BN should involve psychiatric care with psychotherapeutic medications. The need to stop the purging episodes is apparent. Most patients have difficulty following a treatment plan because of the underlying emotional problems associated with the disorder; the treatment plan should include group, family and behavioral therapies.<sup>27</sup>

As a rule, discontinuation of the vomiting will result in a gradual decrease of gland swelling<sup>11,17,28,29</sup> and a return to normal electrolyte levels. Infrequently, the swelling may not resolve,<sup>9,28</sup> which may cause despair to patients who already have a distorted body image.

Attention to the dental status of the patient also is indicated. Our patient was caries-free, and, surprisingly, she did not have the pathognomonic sign of enamel acid erosion from the regurgitated gastric acids. She had good dental health because she practiced meticulous oral hygiene, which included a thorough mouth washing after each emetic episode. We impressed on her the need to continue her oral hygiene practices, as well as to receive fluoride therapy and standard dental care.

## CONCLUSIONS

The etiology of parotid gland swelling in patients with BN can elude dentists, because patients usually are secretive about their purging episodes. The cause of parotid gland enlargement often can be determined from the results of a serum elec-

trolyte study. Early diagnosis can abort a progression to serious medical complications. The need for the patient to seek psychiatric care and discontinue induced vomiting is mandatory. ■

1. Casper RC. The pathophysiology of anorexia nervosa and bulimia nervosa. *Annu Rev Nutr* 1986;6:299-316.
2. Jacobs MB, Schneider JA. Medical complications of bulimia: a prospective evaluation. *Q J Med* 1985;54:177-82.
3. Mitchell JE, Pyle RL, Eckert ED. Frequency and duration of binge-eating episodes in patients with bulimia. *Am J Psychiatry* 1981;138:835-6.
4. Humphries LL. Bulimia: diagnosis and treatment. *Compr Ther* 1987;13:12-5.
5. Oster JR. The binge-purge syndrome: a common albeit unappreciated cause of acid-base and fluid-electrolyte disturbances. *South Med J* 1987;80:58-67.
6. Hall RC, Hoffman RS, Beresford TP, Wooley B, Hall AK, Lubasak L. Physical illness encountered in patients with eating disorders. *Psychosomatics* 1989;30:174-91.
7. Fitzgerald BA, Wright JH, Atala KD. Bulimia nervosa: uncovering a secret disorder. *Postgrad Med* 1988;84:119-23.
8. Haller E. Eating disorders: a review and update. *West J Med* 1992;157:658-62.
9. Mitchell JE, Seim HC, Colon E, Pomeroy C. Medical complications and medical management of bulimia. *Ann Intern Med* 1987;107:71-7.
10. Rockwell WJ. Eating disorders: evaluation and treatment. *N C Med J* 1988;49:533-5.
11. Riad M, Barton JR, Wilson JA, Freeman CP, Maran AG. Parotid salivary secretory pattern in bulimia nervosa. *Acta Otolaryngol* 1991;111:392-5.
12. Brady JP. Parotid enlargement in bulimia. *J Fam Pract* 1985;20:496-502.
13. Ogren FP, Hueter JV, Pearson PH, Antonson CW, Moore GF. Transient salivary gland hypertrophy in bulimics. *Laryngoscope* 1987;97:951-3.
14. Donath K, Seifert G. Ultrastructural studies of the parotid gland in sialadenosis. *Virchows Arch A Pathol Anat Histol* 1975;365:119-35.
15. Chilla R. Sialadenosis of the salivary glands of the head: studies on the physiology and pathophysiology of parotid secretion. *Adv Otorhinolaryngol* 1981;26:1-38.
16. Ascoli V, Albedi FM, De Blasiis R, Nardi F. Sialadenosis of the parotid gland: report of four cases diagnosed by fine-needle aspiration cytology. *Diagn Cytopathol* 1993;9:151-5.
17. Vavrina J, Muller W, Gebbers JO. Enlargement of salivary glands in bulimia. *J Laryngol Otol* 1994;108:516-8.
18. Mandel L, Hamele-Bena D. Alcoholic parotid sialadenosis. *JADA* 1997;128:1411-5.
19. Mehler PS, Wallace JA. Sialadenosis in bulimia: a new treatment. *Arch Otolaryngol Head Neck Surg* 1993;119:787-8.
20. Coleman H, Altini M, Nayler S, Richards A. Sialadenosis: a presenting sign in bulimia. *Head Neck* 1998;20:758-62.
21. Crow SJ, Salisbury JJ, Crosby RD, Mitchell JE. Serum electrolytes as markers of vomiting in bulimia nervosa. *Int J Eat Disord* 1997;21:95-8.
22. Kinzl J, Biebl W, Herold M. Significance of vomiting for hyperamylasemia and sialadenosis in patients with eating disorders. *Int J Eat Disord* 1993;13:117-24.
23. Comerci GD. Medical complications of anorexia nervosa and bulimia nervosa. *Med Clin North Am* 1990;74(5):1293-310.
24. Bonne OB, Bloch M, Berry EM. Adaptation to severe chronic hypokalemia in anorexia nervosa: a plea for conservative management. *Int J Eat Disord* 1993;13:125-8.
25. Greenfeld D, Mickley D, Quinlan DM, Roloff P. Hypokalemia in outpatients with eating disorders. *Am J Psychiatry* 1995;152:60-3.
26. Wolfe BE, Metzger ED, Levine JM, Jimerson DC. Laboratory screening for electrolyte abnormalities and anemia in bulimia nervosa: a controlled study. *Int J Eat Disord* 2001;30:288-93.
27. Herzog DB, Copeland PM. Eating disorders. *N Eng J Med* 1995;313:295-303.
28. Brotman AW, Rigotti N, Herzog DB. Medical complications of eating disorders: outpatient evaluation and management. *Compr Psychiatry* 1985;26:258-72.
29. Peeters F, Meijboom A. Electrolyte and other blood serum abnormalities in normal weight bulimia nervosa: evidence for sampling bias. *Int J Eat Disord* 2000;27:358-62.