

Sponsored by



www.edsdental.com

THE JOURNAL OF THE AMERICAN DENTAL ASSOCIATION



Osteonecrosis of the jaws in patients with a history of receiving bisphosphonate therapy: Strategies for prevention and early recognition

MAICO D. MELO and GEORGE OBEID
J Am Dent Assoc 2005;136;1675-1681

The following resources related to this article are available online at jada.ada.org (this information is current as of February 9, 2010):

Updated information and services including high-resolution figures, can be found in the online version of this article at:

<http://jada.ada.org/cgi/content/full/136/12/1675>

This article appears in the following **subject collections**:

Endodontics <http://jada.ada.org/cgi/collection/endodontics>

Information about obtaining **reprints** of this article or about permission to reproduce this article in whole or in part can be found at:

<http://www.ada.org/prof/resources/pubs/jada/permissions.asp>

Osteonecrosis of the jaws in patients with a history of receiving bisphosphonate therapy

Strategies for prevention and early recognition

MAICO D. MELO, D.M.D.; GEORGE OBEID, D.D.S.

Bisphosphonates, inhibitors of osteoclasts, have been used for many years in the treatment of resorptive bone diseases including osteoporosis, Paget's disease and hypercalcemia related to malignancy. However, bisphosphonates also have been shown to inhibit angiogenesis and induce apoptosis in tumor cells.¹⁻⁶ These features have made bisphosphonates useful in the treatment of metastatic bone disease.

Clinicians need to be aware of bisphosphonate-related osteonecrosis because they are in a position to recognize and possibly prevent this complication of cancer treatment.

BACKGROUND

Several clinical trials have demonstrated the beneficial effects of bisphosphonates in reducing skeletal complications such as pain and pathological fracture in patients with bone metastases.⁷⁻¹⁰ On the basis of the results of these trials, oncologists commonly prescribe bisphosphonates to treat bone lesions of multiple myeloma and metastatic bone lesions in patients with breast and prostate cancer.^{11,12} Recently,

the indications for bisphosphonate treatment were expanded to include osteolytic lesions from any solid tumor, which has resulted in a marked increase in the use of bisphosphonates.¹³

Background. Bisphosphonates, inhibitors of osteoclasts, have been shown to alleviate many of the devastating consequences associated with metastatic bone disease. However, recent reports have shown that bisphosphonates may cause osteonecrosis of the jaws. Since the publication of these initial reports, the authors have treated several patients with osteonecrosis of the jaws who had a history of receiving bisphosphonate therapy.

Methods. The authors reviewed the medical records of patients who visited their clinic between September 2003 and December 2004 and who had osteonecrosis of the jaws and a history of having received bisphosphonate therapy but no irradiation to the head and neck.

Results. Eleven patients (four female and seven male) with a mean age of 69 years were included in this report. They had received bisphosphonate therapy for a mean duration of 34 months. Radiographic data showed loss of bone density at sites of osteonecrosis, and histologic examination demonstrated necrosis of bone without evidence of metastases.

Conclusions and Clinical Implications.

Further research is required for better understanding of the role of bisphosphonates in the development of osteonecrosis of the jaws. Until more is known, the authors recommend that measures be taken to prevent osteonecrosis in those at risk, including identifying patients with a history of having received bisphosphonate therapy before they undergo dental surgery. To help identify such patients, the authors propose the use of a screening questionnaire. When feasible, physicians should consult with their patients' general dentists or oral surgeons before patients begin bisphosphonate therapy.

Key Words. Bisphosphonates; osteonecrosis; bone disease; malignancy.

TABLE

DEMOGRAPHIC DATA FOR PATIENTS WITH OSTEONECROSIS OF THE JAWS AND A HISTORY OF BISPHOSPHONATE INFUSION THERAPY.

PATIENT NO.	SEX	AGE (YEARS)	ONCOLOGIC DIAGNOSIS	BISPHOSPHONATE* (NO. OF MONTHS OF THERAPY)	SITE OF NECROSIS	TREATMENT
1	Female	73	Breast cancer	Pamidronate (12)/zoledronic acid (10)	Maxilla	Partial maxillectomy
2	Male	82	Multiple myeloma	Pamidronate (32)	Mandible	Sequestrectomy
3	Female	83	Breast cancer	Zoledronic acid (16)	Mandible	Sequestrectomy
4	Male	60	Multiple myeloma	Zoledronic acid (13)	Mandible	Sequestrectomy
5	Male	61	Multiple myeloma	Pamidronate (20)	Mandible	Sequestrectomy
6	Male	59	Lung cancer	Zoledronic acid (38)	Mandible	Sequestrectomy
7	Female	60	Multiple myeloma	Pamidronate (70)	Maxilla and mandible	Conservative treatment
8	Male	67	Multiple myeloma	Pamidronate (29)	Maxilla	Conservative treatment
9	Female	67	Breast cancer	Pamidronate (13)/zoledronic acid (23)	Mandible	Conservative treatment
10	Male	80	Multiple myeloma	Pamidronate (30)/zoledronic acid (16)	Mandible	Partial mandibulectomy
11	Male	79	Multiple myeloma	Zoledronic acid (18)	Mandible	Sequestrectomy

* Dosing for bisphosphonate infusions was as follows: pamidronate (90 milligrams) was administered every three to four weeks, and zoledronic acid (4 mg) was administered once a month.

Although extensive data demonstrate the beneficial effects of bisphosphonates in the treatment of osteolytic lesions, Marx¹⁴ and Ruggiero and colleagues¹⁵ recently reported that bisphosphonates—particularly the more potent nitrogen-containing bisphosphonates pamidronate and zoledronic acid—are capable of causing osteonecrosis of the jaws. We were interested to learn of this complication because we have been involved in the treatment of several patients with osteonecrosis of the jaws and a history of receiving bisphosphonate therapy who had not received radiation therapy to the head and neck region. This latter fact is significant because the lesions we observed resembled those seen in osteoradionecrosis, a potentially devastating condition that develops frequently after tooth extraction, but the lesions could not be attributed to radiation exposure.

In an attempt to better understand the pathophysiology of the osteonecrosis seen in these patients, we reviewed the literature. We propose that bisphosphonate-related osteonecrosis is a multifactorial process resulting from an alter-

ation in bone homeostasis including inhibition of angiogenesis.¹⁶ We describe several patients with bisphosphonate-related osteonecrosis of the jaws and offer recommendations for early recognition and prevention.

SUBJECTS AND METHODS

In accordance with the office of the Institutional Review Board, Washington Hospital Center, Washington, we performed a review of medical records of patients visiting our clinic between September 2003 and December 2004 who had osteonecrosis of the jaws. Patients with a history of head and neck irradiation were excluded from this series.

From September 2003 to December 2004, we saw 11 patients with osteonecrosis of the jaws and a history of bisphosphonate therapy in our clinic for consultation and treatment (Table). Four female and seven male patients ranging in age from 59 to 83 years (mean age, 69 years) were included in this series. These patients had a history of receiving pamidronate only (four of 11 patients), zoledronic acid only (four of 11 patients)

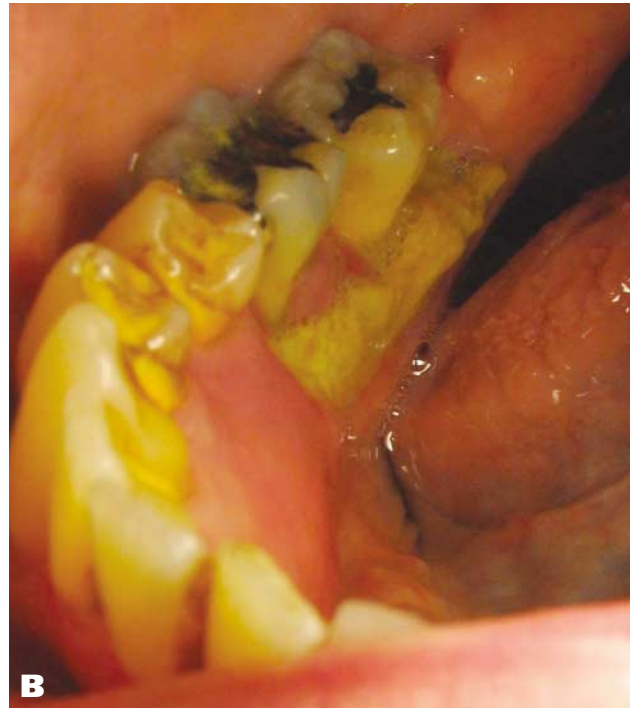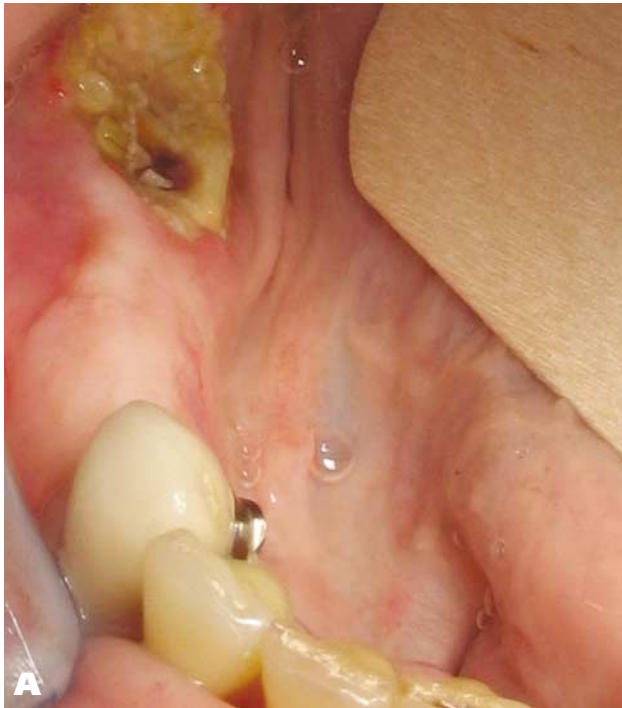


Figure 1. Clinical photographs of patients with osteonecrosis and a history of having received bisphosphonate therapy. A. Nonhealing extraction socket of nine months' duration in the lower right mandible of a patient with a history of multiple myeloma who received zoledronic acid therapy. B. Spontaneous lesion that developed in the right posterior mandible near the mylohyoid line in a patient with a history of multiple myeloma who received zoledronic acid therapy.

or pamidronate initially and then zoledronic acid (three of 11 patients) for the treatment of oncologic disease. The mean duration of bisphosphonate therapy was 34 months.

The primary oncologic diagnoses included multiple myeloma (seven of 11 patients), breast cancer (three of 11 patients) and lung cancer (one of 11 patients). Eight patients had mandibular lesions only (four unilateral and four bilateral), two patients had maxillary lesions only (both unilateral) and one patient had bilateral lesions in the maxilla and mandible. Clinical photographs of the lesions demonstrate the bony exposures and soft-tissue inflammation that we observed (Figure 1). Patients' symptoms varied and included pain, swelling and foul-tasting discharge, often originating at sites of previous dental extraction.

Nine of 11 patients reported a history of recent dental surgery at the site of osteonecrosis. However, in the case of patient no. 5, necrosis of the mandible developed in the absence of any dental procedures or readily identifiable cause, such as an ill-fitting denture. In the case of patient no. 7, we believe that ill-fitting dentures were partly responsible for the lesions that developed many years after she underwent multiple dental extractions.

RESULTS

Panoramic radiographs demonstrated regions of osteolytic changes corresponding to the sites of the bony lesions (Figure 2). In cases of mandibular involvement, extension into or beyond the inferior alveolar canal was not uncommon (two of nine patients). We also noted that these patients had paresthesia along the distribution of the corresponding mandibular branch of the trigeminal nerve. On microscopic examination, all of the analyzed specimens exhibited necrotic bone with associated bacterial debris and granulation tissue, without evidence of metastatic disease (Figure 3, page 1679).

DISCUSSION

Several well-described indications exist for bisphosphonate therapy, including intravenous infusions of pamidronate or zoledronic acid for the treatment of osteolytic lesions related to malignant disease. Several studies⁷⁻¹⁰ have documented the benefits of these agents in reducing the skeletal complications related to malignancy. However, several recent reports¹⁴⁻¹⁸ have described an increased risk of developing osteonecrosis associated with bisphosphonate

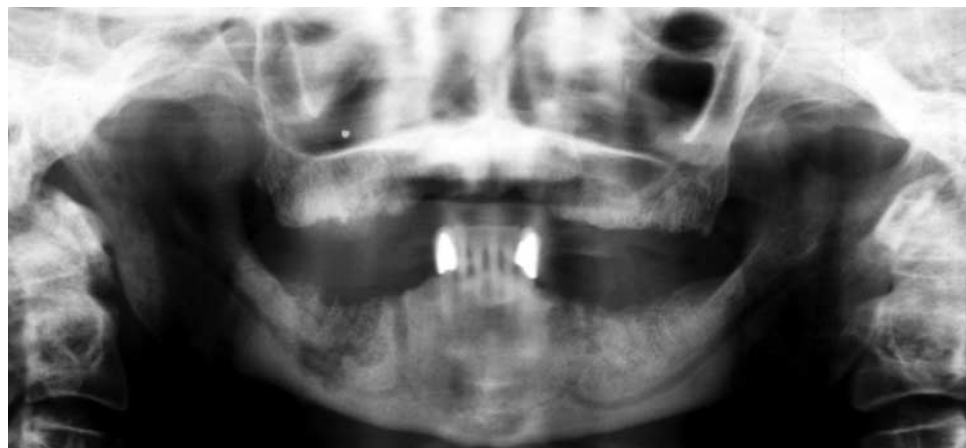


Figure 2. Panoramic radiograph demonstrating osteolysis with typical mottled pattern of bone in the mandible of a patient with a history of having received zoledronic acid therapy. The extension of the osteolysis into the inferior alveolar canal on the right side correlated with mandibular nerve paresthesia.

therapy. In one of these studies,¹⁸ the authors reviewed the dental records of 124 patients receiving bisphosphonate therapy for malignant bone disease and found that 13 patients had osteonecrosis of the jaws. Despite these reports, many oncologists and dentists remain largely unaware of this potential complication.

Osteonecrosis of the jaws. We have described several patients with osteonecrosis of the jaws that resembled lesions seen in osteoradionecrosis. However, none of the patients had a history of undergoing head and neck radiation therapy. All of the patients had a history of oncologic disease and had received pamidronate, zoledronic acid or both as part of their treatment regimen. Pamidronate and zoledronic acid are both nitrogen-containing bisphosphonates that are administered as infusions. Pamidronate is administered every three to four weeks at a dose of 90 milligrams over a period of two hours or more, while zoledronic acid, a newer-generation bisphosphonate with increased potency, is administered monthly at a dose of 4 mg over a 15-minute infusion period. The shorter infusion time for zoledronic acid is seen as a significant advantage over pamidronate, and many patients who received pamidronate therapy switched to zoledronic acid once it became available.

The duration of bisphosphonate therapy in our group of patients ranged from 18 to 70 months, with a mean duration of 34 months. It is not clear from our small sample size whether the type of bisphosphonate influences the development of the lesions or whether these agents, in combination with other medications, exhibit some synergy in

causing osteonecrosis. However, some recent data suggest that the type of bisphosphonate may influence the onset of osteonecrosis.

In a review of 1,203 patients, Durie and colleagues¹⁹ found that 75 patients had osteonecrosis of the jaws, with a mean time to onset of 18 months after beginning therapy for those receiving zoledronic acid compared with six years for those

receiving pamidronate. This study also identified a greater incidence of osteonecrosis among patients receiving zoledronic acid compared with that for patients receiving pamidronate.¹⁹ Although this report provides additional evidence of the association between bisphosphonates and osteonecrosis of the jaws, it may not accurately reflect the relationship, because the data were obtained retrospectively from patient responses to a Web-based survey. Despite this shortcoming, the study findings reinforce the need for further research regarding the role of bisphosphonates in osteonecrosis to better understand the underlying etiologic factors and associated risk factors.

Although the majority of our patients had a history of recent dental surgery that corresponded with the site of osteonecrosis, this was not observed uniformly. In fact, two patients developed lesions many years after having had any dental surgery. Moreover, patient no. 5 had no history of dental surgery at the site of osteonecrosis, and we considered this case to be an example of spontaneous bisphosphonate-related osteonecrosis. Interestingly, the site of necrosis in this patient was the posterior mandible along the mylohyoid ridge, a site that also is commonly involved in osteoradionecrosis. Ruggiero and colleagues¹⁵ reported spontaneous bisphosphonate-related osteonecrosis, and their findings, similar to ours, were that it occurred less frequently than do lesions associated with dental surgery.

Paresthesia. In two of our patients, the onset of paresthesia of the mandibular branch of the trigeminal nerve was attributed to osteonecrosis

that had extended to the inferior alveolar canal. In one of these patients, we removed a large sequestrum from the posterior right mandible, and the patient reported experiencing a modest improvement in sensation to the cutaneous distribution of the mental nerve. In the second patient, the paresthesia of the mental nerve on the right side of the mandible progressed to profound anesthesia, and we found radiographic evidence of osteolysis into the inferior alveolar canal (Figure 2). The patient refused any surgical intervention but, to date, continues to be followed up.

Comparisons with osteoradionecrosis. It is interesting to note that our patients had lesions resembling those seen in cases of osteoradionecrosis, but they had no history of receiving radiation therapy to the head and neck region. Several authors have proposed that the antiangiogenic properties of bisphosphonates, along with the alteration in bone metabolism mediated by osteoclast inhibition, provide a plausible explanation for the development of bisphosphonate-related osteonecrosis of the jaws.¹⁵⁻¹⁷ Similar to patients with osteoradionecrosis, our patients had exposed necrotic alveolar bone. However, unlike osteoradionecrosis, bisphosphonate-related osteonecrosis does not appear to be amenable to hyperbaric oxygen therapy. In osteoradionecrosis, radiation-induced tissue damage is characterized by hypoxia, hypocellularity and hypovascularity, which is reversible or preventable to some degree with revascularization of bone.^{20,21} By contrast, in bisphosphonate-related osteonecrosis, the alteration in bone metabolism is such that revascularization alone is insufficient to alter the course of the lesions, because bisphosphonates are not metabolized appreciably and have the potential to remain in the bone indefinitely.¹ Thus, attempts to increase the vascularity of the affected bone initially may appear promising, but they are unlikely to be successful in the long term.

For example, we referred one of our patients for hyperbaric oxygen therapy. After the patient received 20 treatments (or dives) of hyperbaric oxygen, the lesions appeared more vascular. On follow-up examination, however, more extensive bone exposure and progression of the lesions were evident. Ruggiero and colleagues¹⁵ also reported that bisphosphonate-related osteonecrosis is refractory to hyperbaric oxygen therapy and advised against using hyperbaric oxygen in the treatment of these patients.

Involvement of the maxilla. Another feature

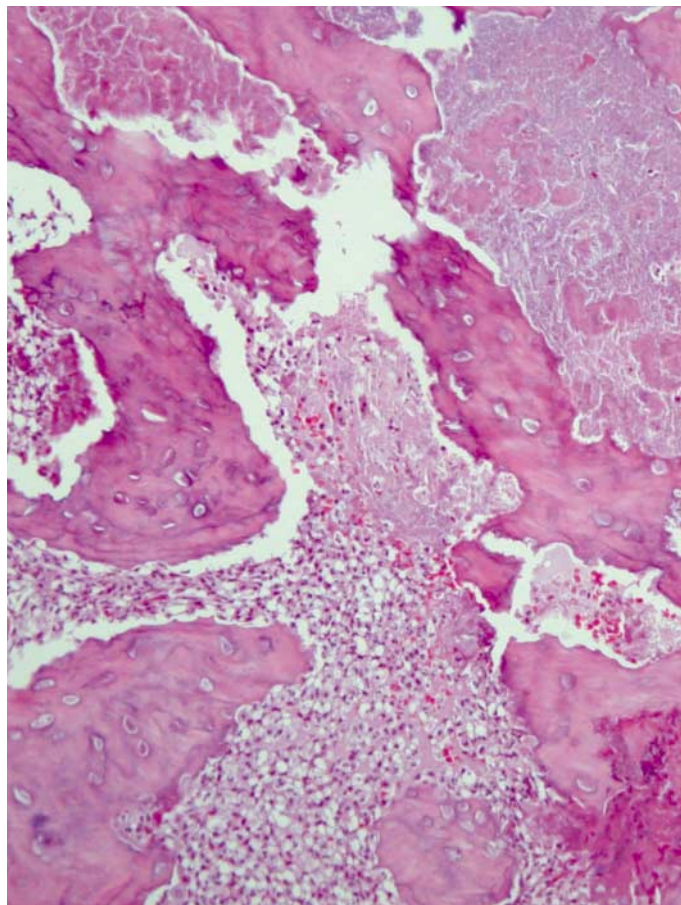


Figure 3. Photomicrograph of a biopsy specimen from a patient with bisphosphonate-related osteonecrosis. The specimen was obtained from the mandible of the patient who had a nonhealing extraction socket and a history of having received pamidronate and zoledronic acid therapy. The specimen shows necrotic bone with empty lacunae and numerous inflammatory cells (hematoxylin-eosin stain, original magnification x100).

that distinguishes bisphosphonate-related osteonecrosis from osteoradionecrosis is the observation that the maxilla commonly is involved in bisphosphonate-related osteonecrosis, whereas this is observed rarely in cases of osteoradionecrosis. Three of our 11 patients had maxillary involvement, and Marx¹⁴ and Ruggiero and colleagues¹⁵ also reported frequent involvement of the maxilla. This difference highlights the fact that in osteoradionecrosis, the risk of radiation-induced injury may be minimized by an inherently rich vascular supply, whereas in bisphosphonate-related osteonecrosis, a rich vascular supply paradoxically may be responsible for the condition, because bisphosphonates reach the bone via the bloodstream. This implies that the entire skeleton may be at risk of developing bisphosphonate-related osteonecrosis, although

BOX

SCREENING QUESTIONS TO IDENTIFY PATIENTS WITH A HISTORY OF BISPHOSPHONATE THERAPY WHO ARE AT RISK OF DEVELOPING OSTEONECROSIS.

QUESTION	YES	NO
Have you received or are you currently receiving medication known as bisphosphonates (for example, zoledronic acid [Zometa] or pamidronate [Aredia])?*	<input type="checkbox"/>	<input type="checkbox"/>
Have you noticed any changes in your mouth or jaws?	<input type="checkbox"/>	<input type="checkbox"/>
Have you had any jaw pain or toothache?	<input type="checkbox"/>	<input type="checkbox"/>
Have you noticed any foul smell, swelling or discharge in your mouth?	<input type="checkbox"/>	<input type="checkbox"/>

* Zometra and Aredia are manufactured by Novartis Pharmaceuticals, East Hanover, N.J.

reports of osteonecrosis at sites other than the jaws have not been reported to our knowledge.

Limited surgical treatment. The fact that bisphosphonates are delivered to the skeleton via the bloodstream creates numerous challenges for health care professionals treating patients with bisphosphonate-related osteonecrosis. In the limited number of patients we have treated surgically, we found it difficult to identify a margin of viable bleeding bone, as one would in cases of osteoradionecrosis. Furthermore, as Ruggiero and colleagues¹⁵ reported, we have not observed satisfactory resolution of lesions after surgical treatment. On the basis of these observations, we recommend limiting surgery to patients who are symptomatic and have lesions that are refractory to conservative antibiotic therapy. In these cases, surgery should be conservative and limited to débridement of necrotic bone, with no attempt made to extend the débridement to margins of viable, healthy bone.

Although much remains to be learned about the complex interactions by which bisphosphonates exert their effects, it is important that health care professionals and patients become aware of the potential risk. Along these lines, Novartis (East Hanover, N.J.), the manufacturer of Aredia (pamidronate) and Zometa (zoledronic acid), recently added osteonecrosis of the jaws to the precautions section of its product monographs (Novartis, unpublished data, 2004). The manufacturer also recommends that patients receiving pamidronate or zoledronic acid treatment avoid invasive dental surgery. It is not clear whether discontinuing bisphosphonate therapy would alter the risk of and/or course of osteonecrosis of the jaws, because the drug

remains in the body for many years.

One of the many unanswered questions is this: what is the probability that a patient beginning bisphosphonate therapy will develop osteonecrosis? We are collaborating with oncologists at Washington Hospital Center to answer this question and to identify strategies to improve the

care of patients. Owing to the variability in symptoms reported by patients and the potential complications of treatment, we recommend the use of a screening questionnaire to identify patients at risk of developing osteonecrosis of the jaws (Box). This questionnaire—alone or as part of the medical history—along with a brief oral examination can be used by general dentists, dental specialists, oncologists and others involved in the care of patients receiving bisphosphonate therapy to help identify those at risk of developing bisphosphonate-related osteonecrosis.

Preventive dentistry measures. Awareness of the potential risk of developing osteonecrosis in patients with a history of having received bisphosphonate therapy should lead to better patient care. However, until more is known about the role of bisphosphonates in the development of osteonecrosis of the jaws, we recommend that measures be taken to prevent osteonecrosis in those at risk. This requires the adoption of appropriate preventive dentistry measures, including controlling dental caries and periodontal disease; avoiding placement of dental implants; and using soft liners on dentures.

Similar to protocols in place at many institutions for preventing osteoradionecrosis in patients about to receive radiation treatment to the head and neck, we recommend that clinicians perform a thorough dental examination and necessary tooth extractions (with time allowed for healing) before intravenous bisphosphonate therapy is initiated. In addition, because dental surgery seems to be a precipitating event in the development of the majority of cases of bisphosphonate-related osteonecrosis, it seems appropriate to recommend alternatives to tooth extraction for patients with

a history of having received pamidronate or zoledronic acid therapy. If alternatives to tooth extraction are not possible, the patient should be aware of the potential risk of developing osteonecrosis, and the surgeon should be prepared to assist the patient should it develop.

Improved patient care requires that general dentists and dental specialists participate with physicians in the treatment of patients at risk of developing bisphosphonate-related osteonecrosis. Incorporating the recommendations outlined above will assist in improving patient care and identifying those at risk. However, we need to stress that the data are insufficient to unequivocally guide the treatment of patients with bisphosphonate-related osteonecrosis. Until adequate data are available, we recommend that clinicians focus their efforts on preventing the progression of lesions and limiting complications related to infection.

To achieve this, practitioners should consider initiating antibiotic coverage with penicillin-type antibiotics or a suitable alternative (such as doxycycline in penicillin-allergic patients), recommending daily rinsing with 0.12 percent chlorhexidine mouthrinse and performing conservative débridement of sequestering bone. Future investigations that identify patients at increased risk of developing osteonecrosis of the jaws and determine the optimal bisphosphonate treatment regimens also will lead to improved patient care.

CONCLUSIONS

In our series of 11 patients, nine had a history of recent dental surgery at the site where osteonecrosis developed. Presumably, in some of these patients, the risk of developing osteonecrosis could have been reduced had their clinicians been aware of the potential risk. One of the remaining two patients had an ill-fitting denture, and the other patient had not experienced any identifiable surgical or traumatic insult.

Despite the morbidity associated with these lesions, the majority of our patients have been able to cope, but many expressed frustration with the lack of curative treatments. We hope that this article will increase awareness of bisphosphonate-related osteonecrosis among general dentists, oral surgeons and oncologists, because these clinicians are in a position to recognize and possibly prevent this complication of cancer treatment. We also recommend that clinicians use a screening ques-

tionnaire to identify at-risk patients and allow them to better counsel their patients. ■

Dr. Melo is a resident, Department of Oral and Maxillofacial Surgery, Room GA-144, Washington Hospital Center, 110 Irving Street N.W., Washington, D.C. 20010, e-mail "mmelo2@msn.com". Address reprint requests to Dr. Melo.

Dr. Obeid is chair, Department of Oral and Maxillofacial Surgery, Washington Hospital Center, Washington.

1. Russell RG, Rogers MJ, Frith JC, et al. The pharmacology of bisphosphonates and new insights into their mechanisms of action. *J Bone Miner Res* 1999;14(supplement 2):53-65.
2. Lee MV, Fong EM, Singer FR, Guenette RS. Bisphosphonate treatment inhibits the growth of prostate cancer cells. *Cancer Res* 2001;61:2602-8.
3. Shipman CM, Rogers MJ, Apperley JF, Russell RG, Croucher PJ. Bisphosphonates induce apoptosis in human myeloma cell lines: a novel anti-tumour activity. *Br J Haematol* 1997;98:665-72.
4. Senaratne SG, Pirianov G, Mansi JL, Arnett TR, Colston KW. Bisphosphonates induce apoptosis in human breast cancer cell lines. *Br J Cancer* 2000;82:1459-68.
5. Wood J, Bonjean K, Ruetz S, et al. Novel antiangiogenic effects of the bisphosphonate compound zoledronic acid. *J Pharmacol Exp Ther* 2002;302:1055-61.
6. Fournier P, Boissier S, Filleul S, et al. Bisphosphonates inhibit angiogenesis in vitro and testosterone-stimulated vascular regrowth in the ventral prostate in castrated rats. *Cancer Res* 2002;62:6538-44.
7. Hortobagyi GN, Theriault RL, Porter L, et al. Efficacy of pamidronate in reducing skeletal complications in patients with breast cancer and lytic bone metastases. Protocol 19 Aredia Breast Cancer Study Group. *N Engl J Med* 1996;335:1785-91.
8. Diel IJ, Solomayer EF, Costa SD, et al. Reduction in new metastases in breast cancer with adjuvant clodronate treatment. *N Engl J Med* 1998;339:357-63.
9. Powles T, Paterson S, Kanis JA, et al. Randomized, placebo controlled trial of clodronate in patients with primary operable breast cancer. *J Clin Oncol* 2002;20:3219-24.
10. Saad F, Gleason DM, Murray R, et al. A randomized, placebo controlled trial of zoledronic acid in patients with hormone-refractory metastatic prostate carcinoma. *J Natl Cancer Inst* 2002;94:1458-68.
11. Hillner BE, Ingle JN, Berenson JR, et al. American Society of Clinical Oncology guideline on the role of bisphosphonates in breast cancer. American Society of Clinical Oncology Bisphosphonates Expert Panel. *J Clin Oncol* 2000;18:1378-91.
12. Berenson JR, Hillner BE, Kyle RA, et al. American Society of Clinical Oncology clinical practice guidelines: the role of bisphosphonates in multiple myeloma. *J Clin Oncol* 2002;20:3719-36.
13. Rosen LS, Gordon D, Tchekmedyian S, et al. Zoledronic acid versus placebo in the treatment of skeletal metastases in patients with lung cancer and other solid tumors: a phase III, double-blind, randomized trial—the Zoledronic Acid Lung Cancer and Other Solid Tumors Study Group. *J Clin Oncol* 2003;21:3150-7.
14. Marx RE. Pamidronate (Aredia) and zoledronate (Zometa) induced avascular necrosis of the jaws: a growing epidemic. *J Oral Maxillofac Surg* 2003;61:1115-7.
15. Ruggiero SL, Mehrotra B, Rosenberg TJ, Engroff SL. Osteonecrosis of the jaws associated with the use of bisphosphonates: a review of 63 cases. *J Oral Maxillofac Surg* 2004;62:527-34.
16. Melo MD, Obeid G. Bisphosphonates and avascular necrosis of the jaws: a pathophysiologic paradox (abstract)? *J Oral Maxillofac Surg* 2004;62(supplement):66.
17. Melo MD, Obeid G. Osteonecrosis of the maxilla in a patient with a history of bisphosphonate therapy. *J Can Dent Assoc* 2005;71(2):111-3.
18. Estilo CL, Van Poznak CH, Williams T, et al. Osteonecrosis of the maxilla and mandible in patients treated with bisphosphonates: a retrospective study. *Proc Am Soc Clin Oncol* 2004;22:750.
19. Durie BG, Katz M, Crowley J. Osteonecrosis of the jaw and bisphosphonates. *N Engl J Med* 2005;353(1):99-102.
20. Marx RE. Osteoradionecrosis: a new concept of its pathophysiology. *J Oral Maxillofac Surg* 1983;41:283-8.
21. Marx RE, Johnson RP, Kline SN. Prevention of osteoradionecrosis: a randomized prospective clinical trial of hyperbaric oxygen versus penicillin. *JADA* 1985;111(1):49-54.