


Sponsored by



www.edsdental.com

THE JOURNAL OF THE AMERICAN DENTAL ASSOCIATION



A multilocular radiolucency

Angela C. Chi, Brad W. Neville and Brent J. Klinger

J Am Dent Assoc 2007;138;1102-1103

The following resources related to this article are available online at jada.ada.org (this information is current as of February 9, 2010):

Updated information and services including high-resolution figures, can be found in the online version of this article at:

<http://jada.ada.org/cgi/content/full/138/8/1102>

This article appears in the following **subject collections**:

Endodontics <http://jada.ada.org/cgi/collection/endodontics>

Information about obtaining **reprints** of this article or about permission to reproduce this article in whole or in part can be found at:

<http://www.ada.org/prof/resources/pubs/jada/permissions.asp>

A multilocular radiolucency

Angela C. Chi, DMD; Brad W. Neville, DDS; Brent J. Klinger, DMD

THE CHALLENGE

An 80-year-old woman was referred by her general dentist to an oral and maxillofacial surgeon (B.J.K.) for evaluation of an asymptomatic radiolucency between the roots of the right mandibular canine and first premolar. Approximately three years previously, her dentist had noted a subtle

radiolucency in this area (Figure 1). However, since that time, the lesion increased in size and developed into a well-defined, multilocular radiolucency (Figure 2). The surgeon enucleated the lesion and submitted the biopsy specimen for histopathologic examination. Figures 3 and 4 are low- and high-power photomicrographs of the specimen, respectively.

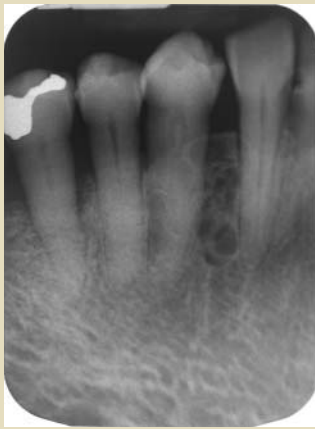

Figure 1. A radiograph obtained three years before the patient visited an oral and maxillofacial surgeon exhibits a subtle area of radiolucency between the right mandibular canine and first premolar.

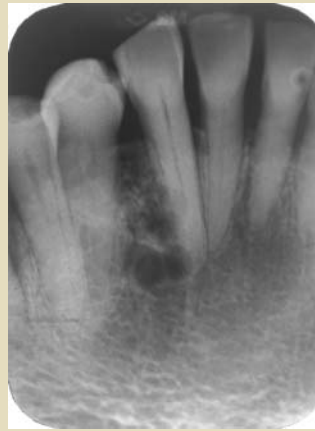


Figure 2. A current periapical radiograph exhibits a well-defined multilocular radiolucency.

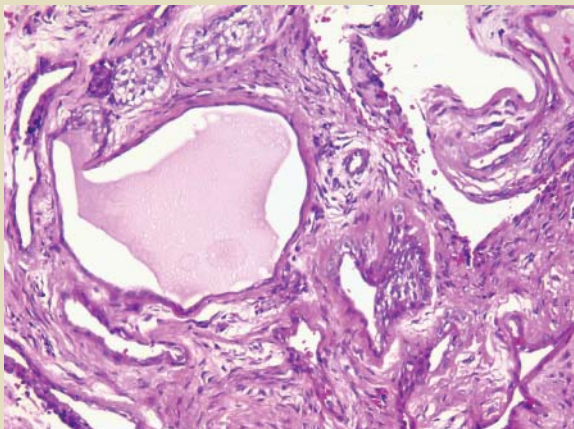


Figure 3. A low-power photomicrograph exhibits multiple cystic spaces (hematoxylin-eosin stain, original magnification $\times 200$).

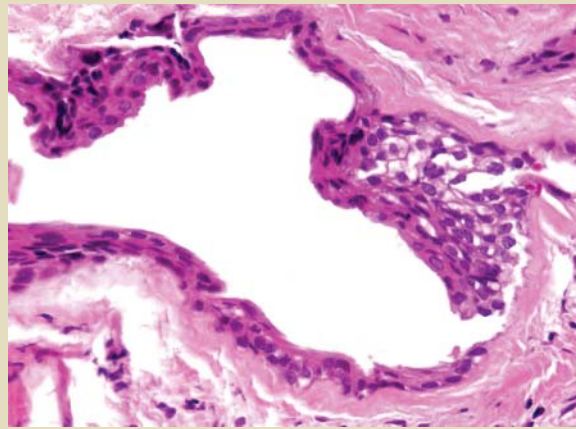


Figure 4. A high-power photomicrograph shows a thin squamous epithelial cyst lining with a focal plaque-like thickening that includes a collection of cells with clear cytoplasm (hematoxylin-eosin stain, original magnification $\times 400$).

Can you make the diagnosis?

- A. odontogenic keratocyst
- B. ameloblastoma
- C. odontogenic myxoma
- D. botryoid odontogenic cyst
- E. calcifying epithelial odontogenic tumor

THE DIAGNOSIS

D. botryoid odontogenic cyst

The botryoid odontogenic cyst (BOC) is a multicystic variant of the lateral periodontal cyst, a developmental cyst believed to arise from remnants of the dental lamina. Weathers and Waldron¹ first described the BOC in 1973, and since then approximately 66 cases have been reported in the literature.² The BOC tends to develop in older adults, with the peak patient age at diagnosis in the sixth and seventh decades and an age range from 20 to 85 years. Similar to the conventional lateral periodontal cyst, the BOC exhibits a predilection for the mandibular canine and first premolar region.^{2,3} Swelling has been reported in more than one-half of cases, although many patients are asymptomatic.² Pain, drainage and paresthesia rarely have been reported.³⁻⁵

The term "botryoid" means "grapelike," and these lesions may appear multilocular radiographically, grossly and/or microscopically. Similar to the lateral periodontal cyst, the microscopic features of the BOC include a thin epithelial cyst lining composed of flattened squamous or cuboidal cells with focal plaque-like thickenings. Clear cells may be seen within the cyst lining or among epithelial rests scattered within the fibrous connective-tissue wall.⁶

Most patients with a BOC are treated with conservative enucleation. However, the BOC exhibits a greater recurrence potential than does the conventional lateral periodontal cyst, with a reported recurrence rate of approximately 33 percent.² This tendency to recur appears to be related to the BOC's polycystic nature, which presumably makes complete surgical removal difficult in some cases.⁶ In addition, some authors have noted that BOCs tend on average to be larger than lateral periodontal cysts⁷; hence, their more expansive nature also may complicate removal. Periodic follow-up is advisable to monitor for potential recurrence.

DIFFERENTIAL DIAGNOSIS

The differential diagnosis for a multilocular radiolucency within the jaws can include numerous conditions. The odontogenic keratocyst and ameloblastoma are the most common considerations, and both of these lesions exhibit a predilection for the posterior mandible. In addition,

a central giant cell granuloma can appear in a similar manner, although this lesion tends to involve anterior portions of the jaws. Less common entities that can be included in the differential diagnosis are odontogenic myxoma, ameloblastic fibroma, central odontogenic fibroma and intraosseous mucoepidermoid carcinoma. A variety of additional rare entities, including odontogenic tumors, odontogenic cysts and other benign lesions, also can appear as a multilocular radiolucency. Because this radiographic pattern is not specific, a biopsy and histopathologic examination are required to reach a definitive diagnosis.

CONCLUSION

The BOC is a multicystic variant of the lateral periodontal cyst, which often manifests as a multilocular radiolucency in the mandibular canine and premolar region. Because additional types of odontogenic cysts as well as tumors and other conditions may appear in a similar manner, a biopsy and histopathologic examination are required to establish the diagnosis. ■

Dr. Chi is an assistant professor, Division of Oral Pathology, Department of Stomatology, College of Dental Medicine, Medical University of South Carolina, 173 Ashley Ave., P.O. Box 250507, Charleston, S.C. 29425, e-mail "chi@musc.edu". Address reprint requests to Dr. Chi.

Dr. Neville is a distinguished university professor, Division of Oral Pathology, Department of Stomatology, College of Dental Medicine, Medical University of South Carolina, Charleston.

Dr. Klinger is in private practice in oral and maxillofacial surgery, Orangeburg, S.C.

Diagnostic Challenge is published in collaboration with the American Academy of Oral and Maxillofacial Pathology and the American Academy of Oral Medicine.

1. Weathers DR, Waldron CA. Unusual multilocular cysts of the jaws (botryoid odontogenic cysts). *Oral Surg Oral Med Oral Pathol* 1973;36(2):235-41.

2. Ramer M, Valauri D. Multicystic lateral periodontal cyst and botryoid odontogenic cyst: multifactorial analysis of previously unreported series and review of literature. *N Y State Dent J* 2005; 71(4):47-51.

3. Gurol M, Burkes EJ Jr, Jacoway J. Botryoid odontogenic cyst: analysis of 33 cases. *J Periodontol* 1995;66(12):1069-73.

4. Kaugars GE. Botryoid odontogenic cyst. *Oral Surg Oral Med Oral Pathol* 1986;62(5):555-9.

5. Lindh C, Larsson A. Unusual jaw-bone cysts. *J Oral Maxillofac Surg* 1990;48(3):258-63.

6. Neville BW, Damm DD, Allen CM, Bouquot JE. Lateral periodontal cyst (botryoid odontogenic cyst). In: Neville BW. *Oral & maxillofacial pathology*. Philadelphia: Saunders; 2002:602-4.

7. de Sousa SO, Campos AC, Santiago JL, Jaeger RG, de Araujo VC. Botryoid odontogenic cyst: report of a case with clinical and histogenetic considerations. *Br J Oral Maxillofac Surg* 1990;28(4):275-6.